

Paramedic Resource Manual

THE ABDOMEN SECTION EIGHT

2005 Update by
Ontario Base Hospital Group Education Subcommittee

OBJECTIVES: THE ABDOMEN

The objectives indicate what you should know, understand and be prepared to explain upon completion of this module. The self-assessment questions and answers will enable you to judge your understanding of the material.

Upon completion of this module, the student should be able to:

1. describe the structure of the abdomen, in terms of muscles, organs, peritoneum, attachments, vasculature and bones.
2. describe the location of intraabdominal organs in terms of anatomical landmarks, and/or quadrants and regions.
3. describe the location, within the abdomen, of the abdominal structures in relation to other organs.
4. given an abdominal surgical scar, indicate the probable previous surgical procedure.
5. describe the nature of-somatic and visceral pain.
6. explain “referred pain” and give examples.
7. given a patient presenting with pain/trauma/mass in a given location, be able to describe the likely abdominal structures involved.
8. briefly describe the clinical findings associated with the patient described in objective 7.

If you have studied this subject previously, you may test your ability using the self-assessment questions. If you are able to obtain 90% or greater, you may choose not to do the unit and merely review the sections, or parts of sections, where weakness may exist. If you obtain less than 90%, it is recommended that the module be done in its entirety, stressing areas where more review is needed.

Author’s Note:

Appreciating the three-dimensional orientation of abdominal organs is difficult. If at all possible, I would strongly suggest the student try to attend an autopsy dissection.

INTRODUCTION

Patients often seek emergency care as a result of abdominal pain and trauma. Potentially catastrophic causes of abdominal pain include:

- ruptured abdominal aortic aneurysm
- perforated bowel
- ectopic pregnancy
- ruptured spleen

Victims of motor vehicle collisions often present with blunt abdominal trauma, while victims of crime may suffer stab wounds or gunshot wounds. Either blunt or penetrating trauma is capable of causing life-threatening hemorrhage.

To initiate appropriate prehospital care, the paramedic should have a working knowledge of the anatomy of the abdomen.

ANATOMICAL LANDMARKS

The student should take a few moments to become familiar with the following anatomic terms (Figures 1 and 2).

COSTAL MARGIN	The lower border of the rib cage.
XIPHOID PROCESS	The lower end of the sternum.
PELVIS	A bony framework consisting of the sacrum, ischium, ilium, and pubis. The pelvis protects the urinary bladder and rectum. The internal female genitalia are also within the pelvis (uterus, fallopian tubes and ovaries).
INGUINAL LIGAMENT	A strong band of connective tissue stretching from the ilium to the pubis.
DIAPHRAGM	The strong tendinous membrane separating the thoracic cavity from the abdomen.
RECTUS ABDOMINIS MUSCLE	The strong paired muscles running the length of the abdomen.
THORACIC VERTEBRAE	Numbered I to XII; abbreviated as T1 to T12
LUMBAR VETEBRAE	Components of the lumbar spine; abbreviated as L1 to L5.

The abdomen is bordered by the dome of the diaphragm superiorly and the pelvic organs inferiorly. The abdominal contents consist of the biliary system (liver, gallbladder), pancreas, spleen, the digestive tract (stomach, small bowel, large bowel), the great vessels (aorta, inferior vena cava) and posteriorly the urinary tract (kidneys and ureters).

Paramedics should describe the location of abdominal pain or masses in terms of quadrants or regions (Figure 1). Four quadrants are formed by imaginary lines that cross at the umbilicus; right upper quadrant (RUQ), right lower quadrant (RLQ), left upper quadrant (LUQ) and left lower quadrant (LLQ).

The epigastric region is bordered by the xiphoid process, both costal margins and a horizontal line between L1 and L2.

The right and left flanks are also regions. They are bordered superiorly by the costal margin, inferiorly by the ilium, and extend laterally to approximately the anterior and posterior axillary lines.

FIGURE 1: ANATOMICAL LANDMARKS OF THE ABDOMEN

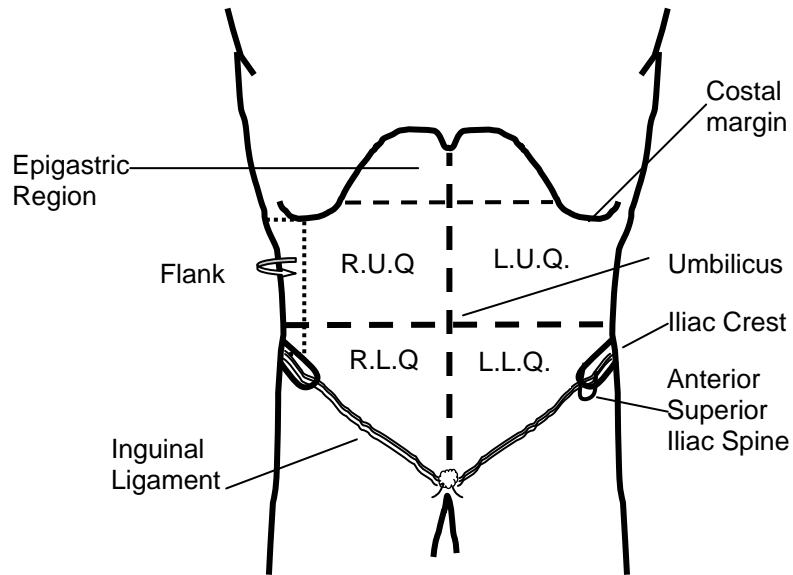
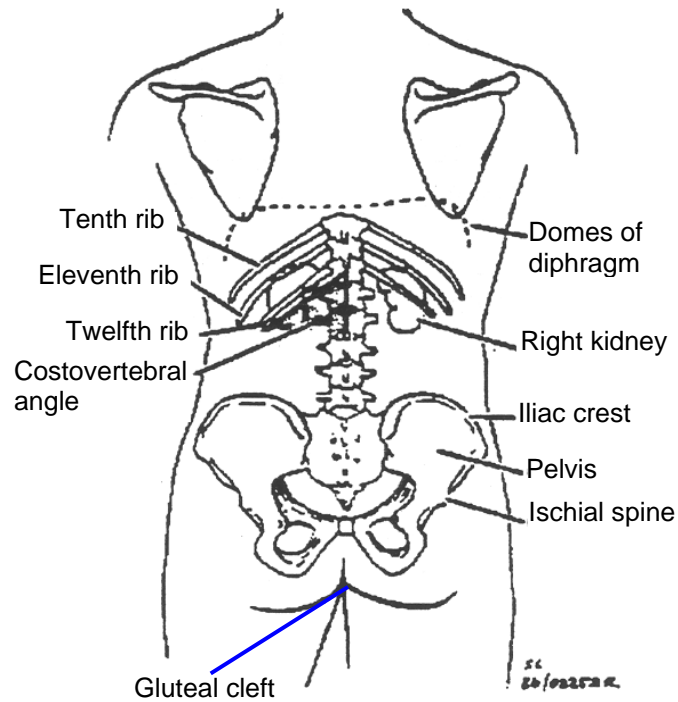


FIGURE 2: THE ABDOMEN (POSTERIOR VIEW)



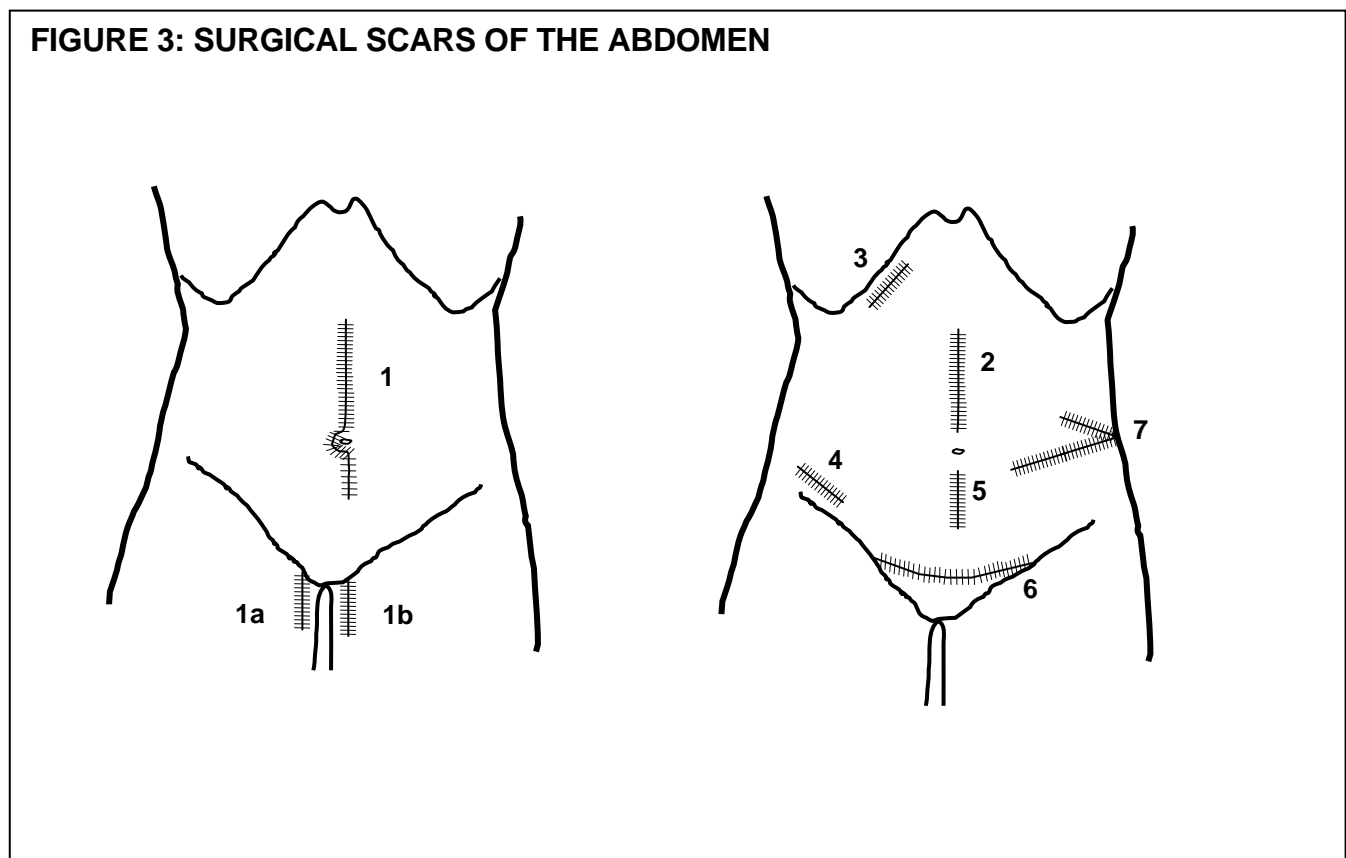
Clinical vignette

If a base hospital physician is to be able to clearly understand the location of a patient's pain, an abdominal mass or a gunshot wound, the paramedic must be able to describe findings in terms common to both.

Valuable information regarding a patient's past history may result from knowledge of the various types of surgical incisions. A patient with many previous abdominal procedures may develop a bowel obstruction from adhesions. Similarly a patient with a previous abdominal bifemoral bypass graft likely has significant atherosclerosis and may present with symptoms resulting from ischemia to the brain (stroke), the heart (myocardial infarct), the bowel (mesenteric occlusion), or the limbs (arterial embolus).

COMMON INCISIONS SITES, ILLUSTRATED IN FIGURE 3, INCLUDE:

- Midline incision (#1) – often used for exploratory laparotomy, e.g. following trauma or aortic aneurysm.
- Midline plus femoral incision (#1 with #1a) – signifies preceding abdominal bifemoral bypass graft.
- Upper midline incision (#2) – may be used for surgical treatment of ulcer disease.
- Right subcostal (Kocher) incision (#3) – 2 small stab-like incision sub-xyphoid and under right costal margin and over belly button commonly used for cholecystectomy (gallbladder removal).
- McBurney incision (#4) – appendectomy.
- Lower midline incision (#5) – used for Caesarian section, hysterectomy, bladder operations or prostate removal.
- Lower transverse (Pfannenstiel) or “bikini” incision (#6) – also used for Caesarian section.
- Renal surgery scar (#7) – for any surgical procedure involving the kidney.



ABDOMINAL WALL

The anterior abdominal wall is a muscular structure. The muscles originate from the lower rib cage and lumbar spine and attached to the ilium and pubis in the pelvis.

The central muscle of the abdomen is a pair of muscles called the rectus abdominis muscle. Three other muscles are lateral to the rectus and are named the external oblique muscle, the internal oblique muscle and the transversus abdominis muscle. The tendinous portion of the external oblique and internal oblique muscles form the inguinal ligament in the groin. Posteriorly, the quadratus lumborum and a portion of the transversus abdominis make up the abdominal wall.

ABDOMINAL SPACES

Before describing the relationship of the various abdominal organs, it is important to understand the concept of the peritoneum.

The peritoneum is a thin layer of connective tissue that forms the inner lining of the abdominal wall and also covers many abdominal organs. The portion of peritoneum that lines the abdominal wall is referred to as parietal peritoneum. The portion that covers an abdominal organ is referred to as visceral peritoneum. The space between the parietal and visceral peritoneum is known as the peritoneal cavity.

The aorta, kidneys and pancreas are covered only anteriorly by the peritoneal reflection and are referred to as retroperitoneal structures.

Posterior to the peritoneal cavity is the retroperitoneal space. A large amount of blood can accumulate here. This is often an area of hidden blood loss as a result of pelvic fractures or rupture of an abdominal aortic aneurysm.



Clinical vignette

Pain, anxiety, fear and cold hands can cause a patient to involuntarily tense the abdominal muscles and make palpation impossible. Ideally the abdominal exam should take place with the patient lying supine, with arms at his side such that the abdomen is relaxed. Slow gentle palpations, beginning in the area that hurts least, facilitates abdominal palpation.

Defects in the abdominal wall are known as hernias. Hernias most commonly occur in the groin (inguinal hernias) but may also be found at the umbilicus (umbilical hernia) or in a previous abdominal incision (incisional hernia).

ABDOMINAL PAIN

Pain in the abdomen generally results from one of three mechanisms:

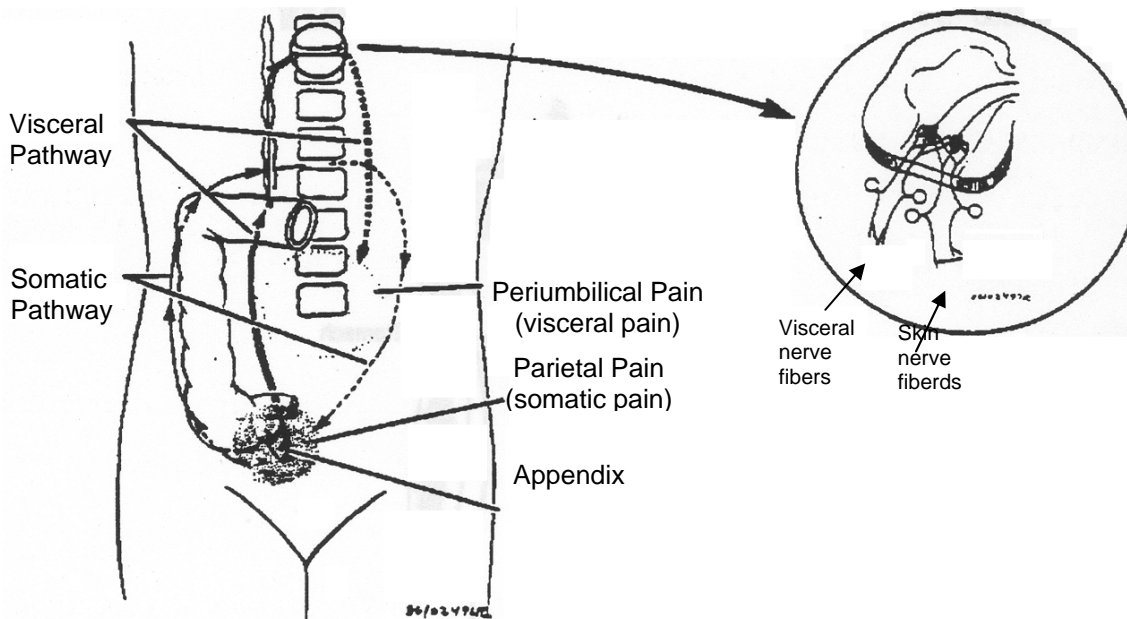
1. Distention of a hollow viscus, e.g. bowel obstruction, early appendicitis, or renal colic (ureter).
2. Ischemia, e.g. mesenteric artery occlusion (the main artery to the bowel becomes occluded and bowel becomes gangrenous).
3. Inflammation, e.g. acute cholecystitis, pancreatitis, late appendicitis.

Two types of pain are recognized – visceral and somatic.

Visceral pain results from increased tension in the wall of a hollow viscus, distention of a hollow viscus and ischemia. This discomfort tends to be dull, poorly localized and is often accompanied by sweating, nausea and vomiting. Early in the course of appendicitis, patients complain of dull crampy periumbilical pain which is poorly localized, often accompanied by nausea and vomiting. This is an excellent example of visceral pain, caused by distention of the appendix with secretions.

Somatic pain arises from the abdominal wall (skin and muscle), the parietal peritoneum and the diaphragm. This type of pain is sharper and better localized to the site of stimulation than visceral pain. Late in the course of appendicitis when the parietal peritoneum covering the appendix becomes inflamed, patients complain of sharp, severe, right lower quadrant pain and exhibit muscular rigidity. This well localized discomfort is somatic pain.

FIGURE 4: EXAMPLE OF SOMATIC AND VISCERAL PAIN PATHWAYS



Clinical vignette

To review then, during the course of an attack of appendicitis, a patient first notes dull, poorly localized visceral pain resulting from distension of the hollow appendix. Later, the patient feels a well-localized, sharp, severe pain (somatic pain) resulting from inflammation of the parietal peritoneum.

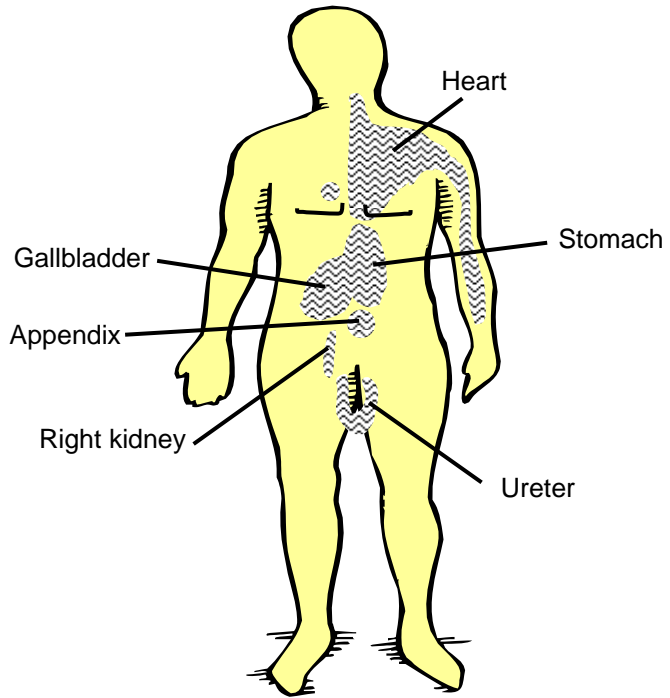
REFERRED PAIN

One must also be cautious in evaluating patients with abdominal discomfort, as pain may be referred to the abdomen from other structures. A classic example of this “referred pain” is the patient with epigastric pain from an inferior myocardial infarction.

The phenomenon of referred pain occurs because the nerves from some abdominal structures feed into the spinal cord at a considerable distance from the diseased organ.

Pain from the abdomen may be referred to other areas, e.g. right scapular pain referred from the gallbladder and shoulder tip pain referred from the diaphragm, or ovaries and fallopian tubes. The diaphragm is innervated from cervical nerves C₃, C₄ and C₅. Hence with diaphragmatic irritation, pain is felt over the shoulder – the area of skin supplied by C₃ and C₄.

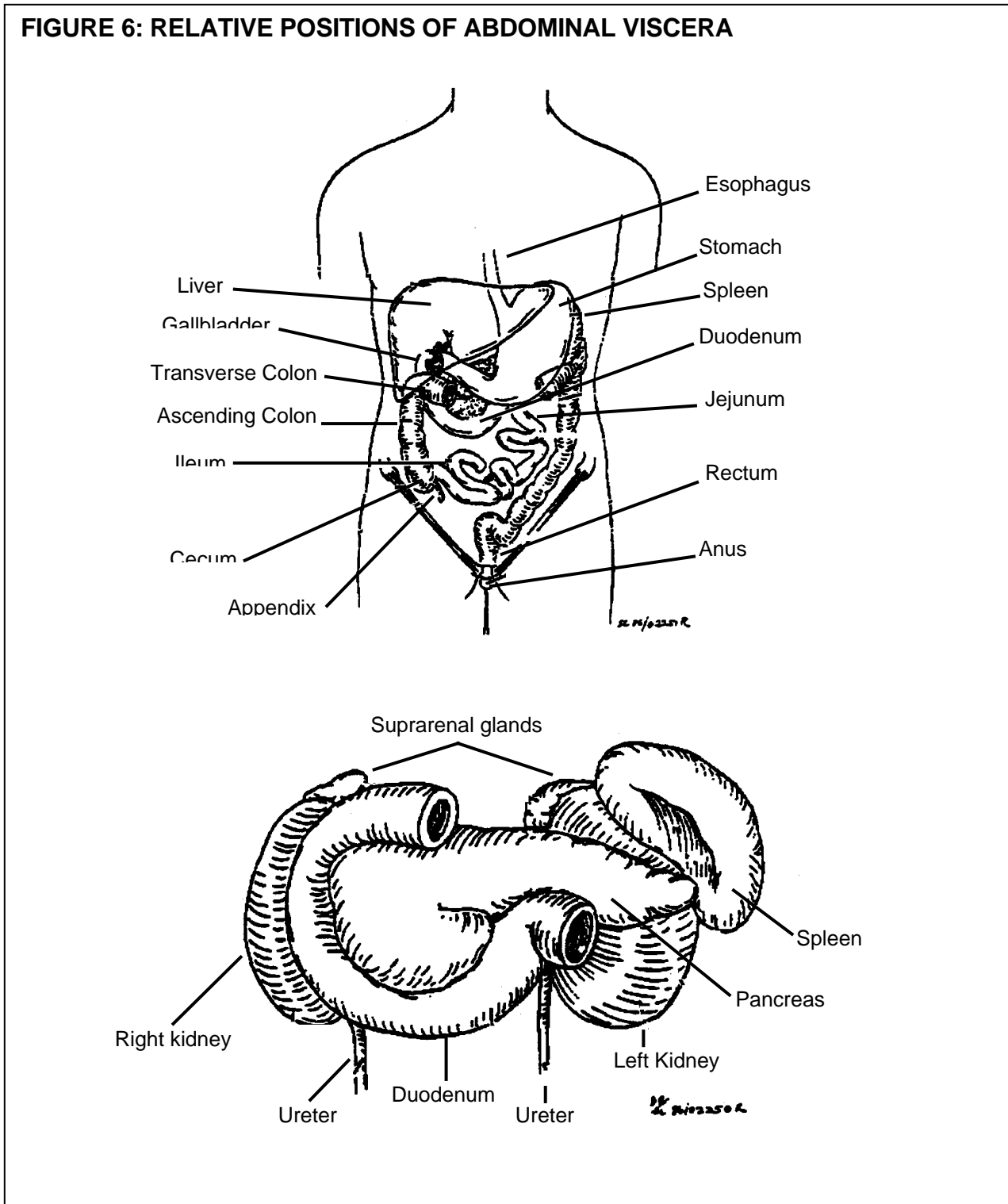
FIGURE 5: SURFACE AREAS OF REFERRED PAIN



ABDOMINAL ORGANS

The abdomen contains a number of organs. The position of these in relationship to each other is illustrated in Figure 6. The text which follows provides a brief description of each organ.

FIGURE 6: RELATIVE POSITIONS OF ABDOMINAL VISCERA



LIVER

The liver is a large triangular-shaped organ weighing about 2 kilograms. Its function as a gland is both exocrine (production of bile) and endocrine (the production of hundreds of proteins which aid protein and fat metabolism). The liver is also responsible for the conversion of excess glucose to glycogen and is the main storage organ for glycogen.

Found in the right upper quadrant of the abdomen, the superior aspect of the liver is smooth and convex, resting under the diaphragm. Most of the gland lies behind the rib cage with only about 1 cm projecting below the costal margin in the mid-clavicular line. Hepatic enlargement (hepatomegaly) is commonly associated with many conditions. In these cases the liver may project significantly below the costal margin.



Clinical vignette

Administration of Glucagon to a hypoglycemic diabetic will breakdown glycogen to free glucose. Unfortunately, if a single dose of Glucagon does not result in an improvement of signs and symptoms, glycogen stores in the liver may be depleted and subsequent doses *may* not be effective.

The gallbladder lies closely adherent to the inferior aspect of the liver (located at about the 9th costal cartilage in the midclavicular line). The gallbladder stores bile, which is secreted from the liver. Bile flows from the liver through the bile ducts into the intestine (duodenum).



Clinical vignette

Blunt trauma to the right upper quadrant may produce liver lacerations – a cause of intra-abdominal bleeding.

Penetrating trauma in the right upper quadrant may cause damage to the liver, lung, diaphragm lining or colon.

Patients complaining of prolonged right upper quadrant abdominal pain who have tenderness to palpation may have distension (biliary colic) or inflammation of the gallbladder (acute cholecystitis).

SPLEEN

The function of the spleen, a soft-fleshy organ, is to help prevent systemic infection by activation of the immune system. It lies in the left upper quadrant protected by the 9th, 10th, and 11th ribs, running parallel to the 9th rib. The spleen is covered anteriorly by the stomach.

Much smaller than the liver, a normal spleen measures only 13-15 cm in length and 5-8 cm in width (about the size of a clenched fist). Unless the spleen is quite enlarged (at least twice its normal size) it is not palpable below the costal margin.



Clinical vignette

Like hepatic injuries, the spleen is often injured as a result of blunt or penetrating trauma to the left upper quadrant. In particular, because of the spleen's proximity to the ribs, patients with low left-sided rib fractures are at risk of splenic rupture. Interestingly, patients with infectious mononucleosis often develop splenomegaly and are at risk of splenic rupture with very minimal injury.

Pediatric patients are also at higher risk of splenic injury as the growth of the abdominal organs occurs sooner than the growth of the rib cage and therefore organs such as the liver and spleen are more exposed.

PANCREAS

The pancreas lies behind the peritoneum and is therefore a retroperitoneal structure. This gland has both exocrine function (production of digestive enzymes) as well as endocrine (production of insulin and glycogen). Anatomically, the gland lies at the level of L2 anterior to the great vessels and kidneys and behind the stomach. The head of the pancreas lies within the "C" shaped curve of the duodenum while the tail just barely touches the spleen (Figure 6).



Clinical vignette

Patients with pancreatitis complain of severe epigastric pain with radiation through the back. There is usually accompanying nausea and vomiting. The most common causes of pancreatitis are:

- as a result of a gallstone that becomes lodged in the pancreatic duct.
- alcohol abuse.

DIGESTIVE TRACT

The alimentary canal consists of esophagus, stomach, small bowel (duodenum, jejunum, ileum) and large bowel (ascending colon, transverse colon, descending colon). The esophagus lies within the thoracic cavity and will not be discussed here.

STOMACH

The stomach is the first portion of the gastro-intestinal tract below the diaphragm. It is a large "reverse J-shaped" organ. The function of the stomach is to begin the digestion of foods and to propel food into the duodenum.

Within the abdominal cavity, the stomach is only partially covered by the left lobe of the liver. It lies anterior to the pancreas and just under the anterior abdominal wall.



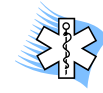Clinical vignette

Since the stomach is relatively unprotected, it is vulnerable to penetrating trauma in the epigastrium and LUQ.

Patients with gastric ulcers complain of midline epigastric burning pain and nausea.

SMALL BOWEL

The duodenum is firmly anchored in the abdominal cavity and like the pancreas is a retroperitoneal structure. The rest of the small bowel, however, is relatively mobile. The blood supply courses through a pedicle or stalk which is referred to as the mesentery. Foodstuff is propelled through the small bowel by peristalsis. The terminal ileum empties into the proximal portion of the large bowel at the cecum.



Clinical vignette

Since the duodenum is firmly anchored and the jejunum is not, this junction is a site of bowel injury and possible transection during a severe acceleration/deceleration type of motor vehicle collisions. Although mesenteric tears are a frequent occurrence in multiply traumatized patients, they usually cause relatively insignificant intraabdominal blood loss.

LARGE BOWEL

The large bowel begins at the cecum – the proximal portion of the **ascending colon**.

Stool is delivered from the small bowel in a liquid state. During propulsion through the colon absorption of water occurs such that solid feces is delivered into the descending (sigmoid) colon.

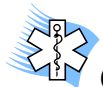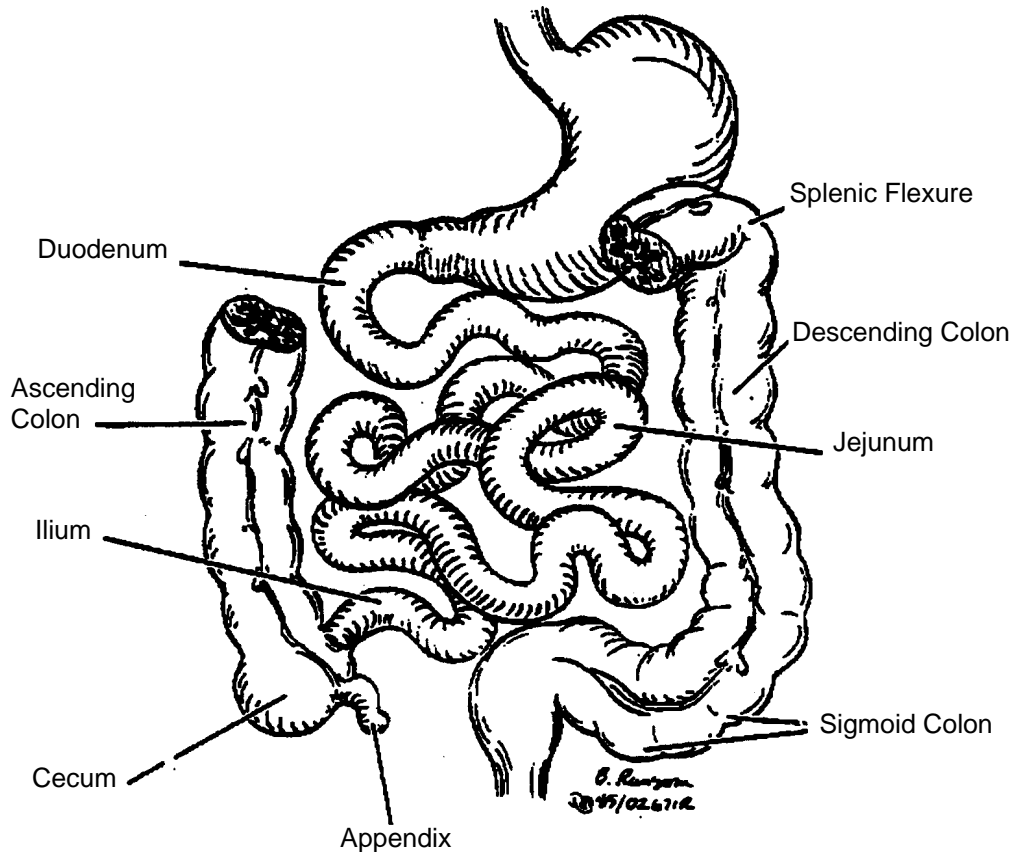
The **vermiform appendix** is a portion of large bowel which is a remnant, in that it has no true function.

The **ascending colon** passes up from the cecum along the right side of the abdominal cavity.

Just below the liver in the right upper quadrant, the bowel turns (at the hepatic flexure) becoming the transverse colon. This portion of the bowel passes anterior to the small bowel to again turn in the left upper quadrant (the **splenic flexure**).

The **descending colon** passes down along the left abdominal wall and in the left iliac fossa the sigmoid colon is formed. The large bowel ends at the rectum – which is really a pelvic organ.

FIGURE 7: DIGESTIVE TRACT (TRANSVERSE COLON REMOVED)



Clinical vignette

Obstruction of the large or small bowel either from within (by hard stool, tumors) or without (adhesions or scarring, tumor, twisting upon itself) is a serious clinical problem. Patients usually present with accompanying abdominal distention, failure to pass gas or stool per rectum, and vomiting.

Another emergent abdominal concern is that of mesenteric vascular occlusion (ischemic bowel). Elderly patients with atrial fibrillation may embolize to the superior or inferior mesenteric artery causing abdominal pain and, if not diagnosed and managed urgently, can go on to have gangrene of a portion of the bowel with the risk of death.

THE GREAT VESSELS

AORTA

The abdominal aorta enters the abdomen at the level of T12 by passing through the diaphragm (Figure 8). Oxygenated blood from the left ventricle is carried to the renal arteries, the mesenteric arteries and the iliac arteries, thus supplying blood to the kidneys, bowel and lower extremities (as well as everything in between!).

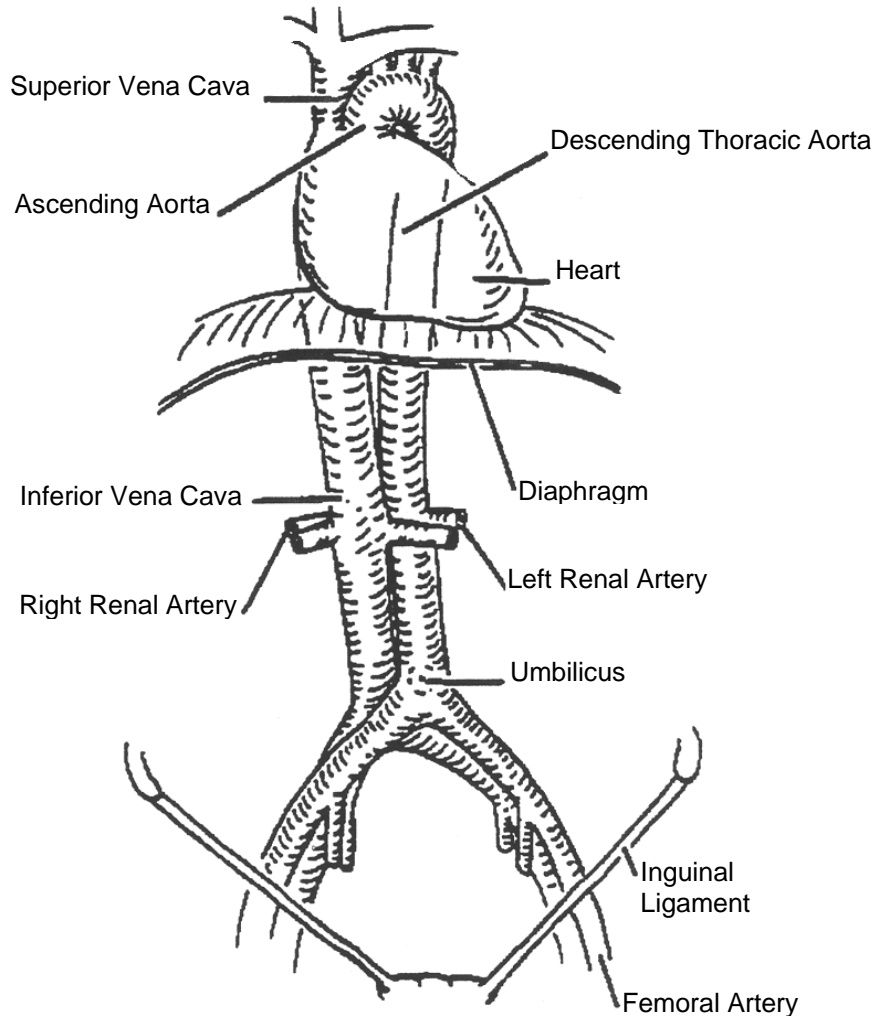
Remember the aorta is a retroperitoneal structure running just anterior to the vertebral bodies behind the pancreas and stomach.

At the level of L4 (at about the umbilicus), the aorta divides into two common iliac arteries. In the pelvis, these iliac arteries are further subdivided into the internal and external iliac vessels.

INFERIOR VENA CAVA

The inferior vena cava (IVC) runs along side the aorta in the abdomen receiving blood from the iliac veins. The IVC is formed at about the level of L5 ascending to the right of the aorta anterior to the vertebral bodies. After passing behind the liver, the inferior vena cava empties blood into the right atrium (at the junction of the superior vena cava).

FIGURE 8: THE IVC AND AORTA



SL 36/02256R



Clinical vignette

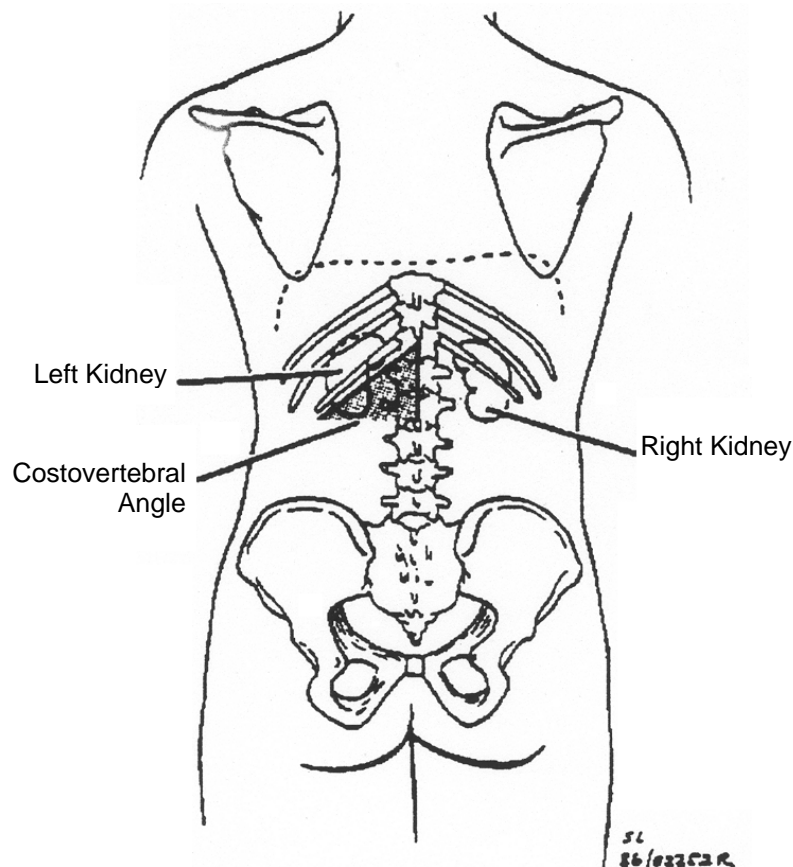
Rupture of an abdominal aortic aneurysm is life threatening. Most abdominal aneurysms (98%) occur below the renal arteries (Figure 8) and may be palpable as a pulsatile mass above the umbilicus or in the epigastrium. Patients with dissecting (blood between the tunica intima and media that separates the layers and the aneurysm expands) or expanding aneurysm present with severe abdominal pain and/or back pain.

URINARY TRACT

The kidneys lie upon the posterior abdominal wall protected by the ribs and are retroperitoneal. Each kidney is bean-shaped and is about 13 cm long by 6 cm wide. The upper pole of each kidney is at about the T11 or T12 level; the right kidney usually being slightly lower than the left.

From the hilum (point of entry/exit of vessels and ducts) of each kidney, a ureter is formed allowing urine to flow down into the urinary bladder. The ureters run retroperitoneally and empty into the bladder in the pelvis.

FIGURE 9: POSTERIOR VIEW OF KIDNEYS



Clinical vignette

Trauma to the flank or abdomen can cause bruising (contusion) or laceration of the kidney. This is usually manifested by hematuria (i.e. gross or microscopic).

Patients with kidney stones and renal colic complain of severe waves of flank or abdominal pain as a result of visceral pain (obstruction of a hollow viscus).

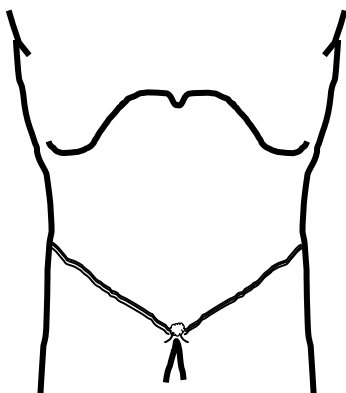
Recall this pain is vaguely localized and usually associated with nausea and vomiting.

**ADVANCED LIFE SUPPORT
PRECOURSE
THE ABDOMEN**

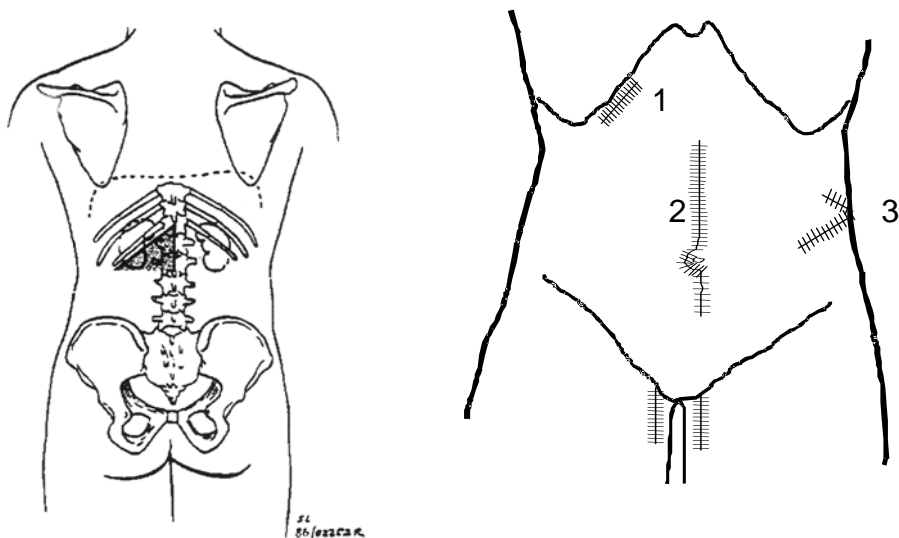
SELF-ASSESSMENT

Marks

- [2] 1. a) On the diagram below place the lines dividing the abdomen into quadrants.
[2] b) Label the quadrants, using the common abbreviations for each.



- [3] 2. a) On the diagrams below draw and label the epigastric region, flanks, and costovertebral angle.
[3] b) Identify the probable surgical procedures performed with the scars labelled 1, 2, and 3.



[2] 3. Name the four muscles which comprise the anterior abdominal wall.

[2] 4. Differentiate between visceral and parietal peritoneum.

[4] 5. Name the organs which come into contact with the spleen.

[1] 6. The pancreas is situated anterior to _____ vertebra.

[2] 7. The posterior landmark for bifurcation of the aorta is _____ vertebra.

[3] 8. Which of the following structures are retroperitoneal?

- | | | | |
|-------------------------------|--------------------------------|-------------------------------|-----------------------------|
| IVC <input type="radio"/> | liver <input type="radio"/> | spleen <input type="radio"/> | colon <input type="radio"/> |
| Kidneys <input type="radio"/> | pancreas <input type="radio"/> | stomach <input type="radio"/> | |
| Ureters <input type="radio"/> | duodenum <input type="radio"/> | aorta <input type="radio"/> | |

[1] 9. Where would you palpate expecting to find the pulsatile mass of an abdominal aneurysm?

[2] 10. Why does the pain of cholecystitis often increase on inspiration?

[1] 11. Fractures of the left-side 9th, 10th and 11th rib are often associated with what underlying injury?

[1] 12. Name the large pair of muscles which tend to hold in the abdominal contents anteriorly.

[2] 13. a) Which area of the abdominal contents is the most prone to shearing injury and why?

b) Assuming the above was an isolated injury, the most likely early clinical finding would be _____ due to _____.

34 TOTAL

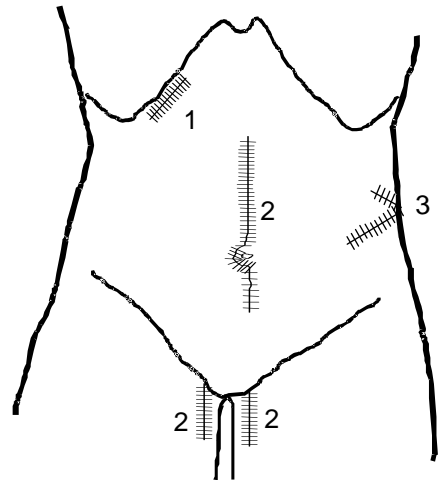
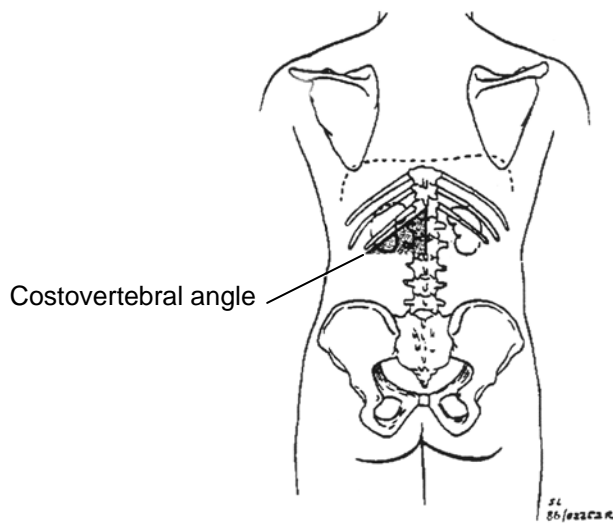
**ADVANCED LIFE SUPPORT
PRECOURSE
THE ABDOMEN**

SELF-ASSESSMENT - ANSWERS

1. 1 mark for each line.
½ mark for each label.

Quadrants:

2. a)



- b)
1. Cholecystectomy
 2. Aorto-bifemoral bypass
 3. Renal surgery

3. Rectus abdominis
Internal oblique
External oblique
Transversus abdominis
4. Parietal peritoneum lines the interior of the abdominal wall. Visceral peritoneum is continuous with the parietal peritoneum, but covers the surface of the organs.
5. Pancreas
Left kidney
Colon
Stomach
6. L2
7. L4
about the umbilical level.
8. Pancreas, duodenum, both kidneys, ureters, aorta, IVC
9. Superior to the umbilicus, in about the midline, or in the epigastric region
10. The gallbladder contacts the liver inferiorly. The liver contacts the diaphragm superiorly. During inspiration the diaphragm descends, increasing downward pressure, and often pain.
11. Rupture of the spleen.
12. Rectus abdominis.
13. a) The junction of the jejunum and the duodenum, due to the fixed position of the duodenum vs. the mobility of the jejunum.
b) RUQ pain due to local peritoneal irritation from the spilled contents of the digestive system.

**ADVANCED LIFE SUPPORT
PRECOURSE
THE ABDOMEN**

EVALUATION

Upon completion of this module, please fill in and return this form to your base hospital co-ordinator.

Your comments will help to ensure that this unit is a useful learning module. Please indicate any problems that you may have encountered. All suggestions for improvement are welcomed.

1. How long did it take to complete this module? Please estimate.

Reading	_____	hours
Self assessment	_____	hours
Total time	_____	hours

2. Were the objectives of the module clearly stated?

yes no
If no, please comment.

3. Did you see any of the resource materials?

yes no
If yes, which items

Were they helpful? _____

4. Were the reference notes adequate?

yes no
If no, please comment.

5. Were the reference notes easy to follow?

yes no

If no, please comment.

6. Were the examples provided satisfactory?

yes no

If no, please comment.

7. Were any of the self-assessment questions poorly worded?

yes no

If yes, please specify.

1. Was the level of the module satisfactory for your program of study?

yes no

If no, please comment.

Base Hospital _____

9. General comments or suggested improvements.